

# A CASE OF OCCIPITAL MENINGOENCEPHALOCYSTO CELE IN A FULLTERM NEONATE

*by* Syatirah Jalaluddin

---

**Submission date:** 18-Sep-2019 12:58AM (UTC+0700)

**Submission ID:** 1174567272

**File name:** Publikasi\_Neonatologi.docx (520.39K)

**Word count:** 1800

**Character count:** 10871

## A CASE OF OCCIPITAL MENINGOENCEPHALOCYSTOCELE IN A FULLTERM NEONATE

Sy<sup>7</sup>irah Jalaluddin<sup>1</sup>, Andi Faradilah<sup>2</sup>

<sup>1</sup>Pediatric Departement, Medical and Health Science Faculty, Alauddin Islamic State University, Makassar, Indonesia

<sup>2</sup>Nutritional Departement, Medical and Health Science Faculty, Alauddin Islamic State University, Makassar, Indonesia

### ABSTRACT

**Background:** The neural tube defect is one of the congenital anomalies which is frequently found in developing countries. A large occipital meningoencephalocystocele possess difficulties in surgical intervention, because the sac usually contains large amounts of cerebrospinal fluid, meninges, brain tissue, and, a higher rate of surgical complications, as well as a difficult positioning at intubation to minimalize the complications.

**Case Presentation:** To report a case of neonate with a large occipital meningoencephalocystocele, which was managed with surgery by removing the extra cranial tissue containing the necrotic brain tissue and the meninges. The patient was discharge with normal wound healing, but ventriculoperitoneal shunt was not performed. Feeding difficulties and poor growth were observed several months after surgery with obvious neurological problems.

**Conclusions:** A through management of meningoencephalocystocele involves many aspects include treatment after surgery was performed.

**Keywords:** occipital encephalocele, meningoencephalocystocele, excision, neonate

### Introduction

Meningoencephalocystocele is a type of encephalocele, a rare congenital anomaly due to neural tube defect. This anomaly marked by the protrusion of neural element, like brain tissue, along with meninges, and cerebrospinal fluid due to the involvement of ventricular system, which extends through a defect in the skull.<sup>1</sup> This congenital anomaly occurs in 0.8–5.6 per 10,000 live births.<sup>2</sup> This defect

occurred due to the failure of ectoderm layer to separate from the neuroectoderm during organogenesis. The exact cause of the condition is still unknown for certain, but environmental factors are thought to have a role.<sup>3,4</sup> This defect can be detected through ultrasonography during antenatal care, and complete evaluation of other abnormalities, whether it is an intracranial or extra cranial anomaly needs to be performed after the diagnosis was established.

The treatment depends on the size, location and severity of the defect. Imaging studies are needed to know the severity of the defect, followed by surgery to repair it. The prognosis for patient with meningoencephalocystocele depends on the size and location of the sac, the presence of brain tissue inside the sac, and other accompanying brain abnormalities. Other influencing factors include hydrocephaly, infections, and other comorbid pathologies. Occipital encephalocele has an extremely high morbidity and mortality in spite of well given treatment before and after surgery.<sup>5</sup>

### Case Presentation

A one-day female neonate admitted in neonatal emergency unit with a swelling at the back of the head noted at birth. The baby was born in primary health center, through normal vaginal delivery, with a little difficulty during labor because of breech presentation. The mother did not have regular antenatal care. The baby was first born child; history of congenital anomaly was denied. She was born full term with birth weight 2,6 kg. She cried immediately, there were no bladder and bowel dysfunction. No convulsion or signs of meningeal irritation, and she was breast feeding well. On local examination, the swelling was spherical, sized 11x6x6 cm,

with little erythema at the center, head circumference was 28 cm. The consistency of the swelling was soft with negative trans illumination test (Figure 1). The vital signs within normal limit, there was no sign of respiratory distress, normal bladder and bowel function.

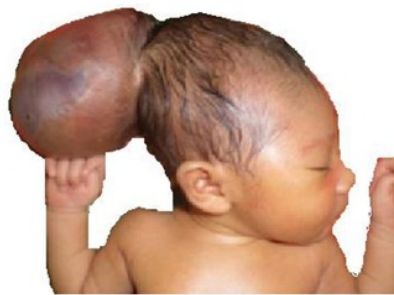

Figure 1. The occipital meningoencephalocele in a full-term neonate

The neurological examination revealed that the patient was conscious and normal suckling reflex. There were no limbs weakness and well muscular tone. The primitive reflexes were normal and symmetrical. The light reflex was normal.

The results of laboratory evaluations were within normal range. The head CT-scan showed a defect on the right occipitoparietal bone accompanied by a protruded sac with mixed density (8,65 – 33,75 HU), the brain tissue and the ventricular system visually distorted, and it

was concluded as a meningoencephalocystocele (Figure 2).

surgery. A little difficulty was noted at the time.

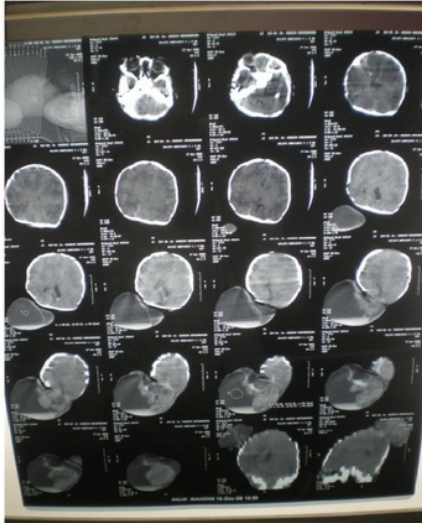


Figure 2. Head CT-scan

The patient was laid in prone position on the operation table, supported on a soft doughnut roll (Figure 3). The surgery aimed to make an excision and to repair the sac. The excision was done by removing the extra cranial tissues (Figure 4), and then closing the defect with durafascial flap. Careful observation and monitoring the baby's vital sign was performed throughout surgery.

After the surgery, there were no evidence of infection and cerebrospinal fluid leakage. The wound healed perfectly, and there were no signs of raised intracranial pressure during hospitalization. She began breast feeding in a week after

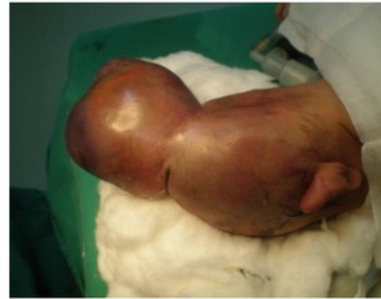

Figure 3. The preoperative view of the patients under general anesthesia

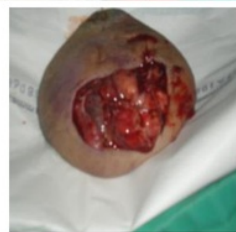
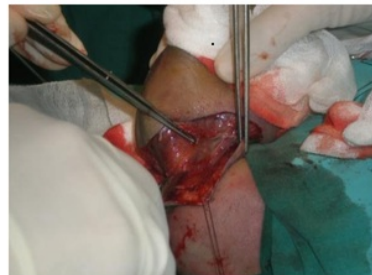
Figure 4. The excision of extra cranial tissue, and the sack containing non-functional brain tissue after removal

Two weeks after surgery, the patient was discharge. The head circumference increased 2 cm, but it was still considered as microcephaly. The

prognosis of this anomaly and the possibility of ventriculoperitoneal shunt have been informed to the mother, but the family refused the procedure.

5 months after surgery, the patients came with feeding difficulty. Physical examination revealed the patient was undernutrition, delayed development with visible signs of hydrocephalus. The family refused to be hospitalized.

### Discussion

The neural tube defect is the leading cause of central nervous system congenital anomaly due to the failure of its closure during fetal period. The exact cause of NTD is unknown, some factors like hyperthermia, drugs, malnutrition, chemical substances, obesity, maternal diabetes, radiation, folic acid deficiency, teratogenic agents, trypan blue, arsenic, and genetic determinant are known to influence the development of central nervous system and can cause encephalocele.<sup>6,7</sup>

Other malformation or chromosomal anomaly can be found in 60% patients with encephalocele. They have higher risk of having hydrocephalus due to aqueduct sylvii stenosis, Chiari malformation, or Dandy-Walker syndrome.<sup>4,7</sup>

The mesodermal defect which cause defect on calvaria, duramater, and the separation of ectodermal surface with neuroectoderm are the main components of meningoencephalocystocele. This cause herniation of CNS, brain tissue and meninx. It can happen in occipital (75%), frontoethmoidal (13-15%), parietal (10-12%) or sphenoidal region.<sup>3,4,8</sup>

The presence of encephalocele lower the survival rate of newborn to 21%, and only half of them can survive. Around 75% of the survivors will suffer from mental retardation, and around 3% had recurrence after surgery.<sup>3,5</sup>

The diagnosis of meningoencephalocystocele in this case was based on history taking, physical examinations and confirmed by head CT-scan. Generally, the neonate was active, there were no signs of neurological defect, positive primitive reflexes, good sucking reflex, although a bit hampered by the mass. Meningoencephalocystocele usually accompanied by other craniofacial abnormality or brain malformations. The symptoms include neurological defects, hydrocephalus, spastic paralysis, microcephaly, ataxia, developmental disorder, visual problems, mental and growth retardation, and seizure. As the presence of associated intracranial pathologies, including brain malformations, is predictive for the

cognitive outcome.<sup>9</sup> In this neonate, we found microcephaly due to the protrusion of brain tissue into the encephalocele pouch. During hospitalization, the baby never had seizure or other noticeable neurological abnormalities.

The management of meningoencephalocystocele was through correction surgery. The treatment of choice is excision of the sac through surgery, followed by dural and cranial defect reparation. The outcome depends on the location and the size of defect. VP-shunt placement of is meant to drain excess cerebrospinal fluid. The final result depends on the amount of normal brain tissue left inside the skull after surgery. The surgery mostly to facilitates the baby's nursing. Furthermore, less brain tissue in the sac made the excision of the sac easier and safer.<sup>2,10</sup>

In our patient, the head circumference increased 2 cm after surgery, but still in the category of microcephaly. This can be caused by the accumulation of CSF due to aqueduct sylvii stenosis, which can be corrected through implementation of VP-shunt. Unfortunately, in this case, the VP-shunt was not performed.

The prognosis of encephalocele depends on the location, size, and the content of the sac. The absent of brain tissue in the sac is a good prognostic

factor. Poor prognosis includes giant posterior encephalocele, the present of hydrocephalus and other systemic abnormalities. Patients with anterior encephalocele has a higher rate of survival rate, compare to the posterior one.<sup>1,3,10</sup>

The most common complications of operation are infection, meningitis, brain damage, and hydrocephalus. Recurrence can happen after surgery. Most neonates with occipital encephalocele will suffer from hydrocephalus. Visual dysfunction, motoric abnormalities and intelligence problems are common in this case. The mortality rate of this case approximately 30% despite the application of appropriate treatments. In this case, the prognosis is poor due to herniation of brain tissue, which probably will cause some serious neurological defects. The involvement of ventricular system in this case can lead to hydrocephalus, which will worsen the prognosis.<sup>1,2,9,11</sup>

### Summary

A case of a female neonate with meningoencephalocystocele was reported. The diagnosis was based on the result of head CT-scan. Surgical intervention consisted of meningoencephalectomy (excision) without VP- shunt was performed. The prognosis of this patient in

term of quo ad vitam was dubia and quo ad sanationem was poor.

## References

1. Pahuja, HD, Deshmukh, SR, Lande, SA, Palsodkar, SR, Bhure, AR. Naesthetic Management of Neonate with Giant Occipital Meningoencephalocele: Case Report. Egyptian Journal of Anaesthesia. 2015. Available at [www.sciencedirect.com](http://www.sciencedirect.com).
2. Ganapathy, A., Sadeesh, T., Swer, MH., Rao, S. Occipital meningoencephalocele with Cleft Lip, Cleft Palate and Limb Abnormalities- A Case Report. Journal of Clinical and Diagnostic Research. 2014; Vol. 8(12). Available at [www.jcdr.net](http://www.jcdr.net).
3. Raja, RA., Qureshi, AA., Memon, AR., Ali, H., Dev, V. Pattern of Encephaloceles: A Case Series. Journal of Ayub Med Coll Abboobad. 2008; 20(1). Available at [www.ayubmed.edu.pk/JAMC/PAST/20-1/Raja.pdf](http://www.ayubmed.edu.pk/JAMC/PAST/20-1/Raja.pdf).
4. Khan AN., Turnbull, I., Macdonald, S., Sabih, D. Encephalocele Imaging. 2019. Available from : <https://emedicine.medscape.com/article/403308-overview#a1>.
5. Kiyamaz, N., Yilmaz, N., Demir, I., Keskin, S. Prognostic factors in patients with occipital Encephalocele. Pediatric Neurosurgery. 2010; 46: 6–11.
6. Jeong, DH., Kim, CH., Kim, MO., Chung H., Kim, TH., Jung, HY. Arnold-Chiari Malformation Type III with Meningoencephalocele: A Case Report. Annals of Rehabilitation Medicine. 2014. Available at <http://dx.doi.org/10.5535/arm.2014.38.3.401>.
7. Kinsman SL & Johnston MV. *Congenital Anomalies of the Central Nervous System in Nelson Textbook of Pediatric*, Kliegman RM e al. 18<sup>th</sup> Edition. Saunders Elsevier. Philadelphia. 2007. Hal: 2447.
8. Jain, K., Sethi, SK., Jain, N., Patodi, V. Anaesthetic management of a huge occipital meningoencephalocele in a 14 days old neonate. Ain-Shams Journal of Anesthesiology. 2018. Available at <https://doi.org/10.1186/s42077-018-0005-7>.
9. Kasprian, GJ., Paldino, MJ., Mehollin-Ray, AR., Shetty, A., Williams, JL., Lee, W., Cassady, CI. Prenatal Imaging of Occipital Encephaloceles. Fetal Diagnosis and Therapy. 2015; 37:241-248.
10. Ahlawat, G., Chhabra, S., Ahlawat, MS. 2014. Occipital Meningoencephalocele - Anaesthetic

Challenges: A Case Report. World  
Journal of Pharmaceutical Research.  
Volume 3, Issue 3. Available at  
[www.wjpr.net](http://www.wjpr.net).

11. Alwahab, A., Kharsa, A., Nugud, A.,  
Nugud S. Occipital  
Meningoencephalocele case report and  
review of current literature. Chinese  
Neurosurgical Journal. 2017.  
Available at [www.biomedcentral.com](http://www.biomedcentral.com).

10



# A CASE OF OCCIPITAL MENINGOENCEPHALOCYSTOCELE IN A FULLTERM NEONATE

## ORIGINALITY REPORT

16%

SIMILARITY INDEX

14%

INTERNET SOURCES

10%

PUBLICATIONS

7%

STUDENT PAPERS

## PRIMARY SOURCES

1	<a href="http://rarediseases.info.nih.gov">rarediseases.info.nih.gov</a> Internet Source	4%
2	<a href="http://pdfs.semanticscholar.org">pdfs.semanticscholar.org</a> Internet Source	2%
3	<a href="http://jcdr.net">jcdr.net</a> Internet Source	1%
4	<a href="http://www.emedicine.com">www.emedicine.com</a> Internet Source	1%
5	Submitted to Glasgow Caledonian University Student Paper	1%
6	<a href="http://benthamopen.com">benthamopen.com</a> Internet Source	1%
7	Darmawansyih Darmawansyih. "AN OVERVIEW ABOUT THE USE OF ANTIBIOTIC IN PREGNANCY AND NURSING MOTHER IN MAKASSAR", MOLUCCA MEDICA, 2017 Publication	1%

8	Internet Source	1%
9	<a href="http://www.fspog.com">www.fspog.com</a> Internet Source	1%
10	Submitted to Oxford Brookes University Student Paper	1%
11	<a href="http://www.svmcpondy.com">www.svmcpondy.com</a> Internet Source	1%
12	<a href="http://link.springer.com">link.springer.com</a> Internet Source	1%
13	<a href="http://citeseerx.ist.psu.edu">citeseerx.ist.psu.edu</a> Internet Source	<1%
14	Kreutzer, . "Stiff-Legged Gait", Encyclopedia of Clinical Neuropsychology, 2011. Publication	<1%
15	Submitted to Chulalongkorn University Student Paper	<1%

Exclude quotes      On  
Exclude bibliography      Off

Exclude matches      Off