

# Evaluation of Outer Retinal Layer Thickness in Normal and Glaucomatous Eyes using Spectral Domain Optical Coherence Tomography

*by Miftahul Akhyar Latief Ulfah Rimayanti*

---

**Submission date:** 05-Jun-2023 08:26AM (UTC+0700)

**Submission ID:** 2108959002

**File name:** uter\_Retinal\_Layer\_Thickness\_in\_Normal\_and\_Glaucomatous\_Eyes.pdf (1.53M)

**Word count:** 6366

**Character count:** 32133

## Evaluation of Outer Retinal Layer Thickness in Normal and Glaucomatous Eyes using Spectral Domain Optical Coherence Tomography

Miftahul Akhyar LATIEF<sup>1,2,3</sup>\*, Diah Gemala IBRAHIM<sup>1,3,\*</sup>, Ulfah RIMAYANTI<sup>3,4</sup>,  
Tomoyuki AKITA<sup>5</sup>, Junko TANAKA<sup>5</sup>, and Yoshiaki KIUCHI<sup>1</sup>

1) Department of Ophthalmology and Visual Sciences, Graduate School of Biomedical Sciences, Hiroshima University, 1-2-3 Kasumi, Minami-ku, Hiroshima 734-8551, Japan

2) Medical Faculty of Muhammadiyah University, Jln. Sultan Alauddin No.259, Kota Makassar, South Sulawesi 90221, Indonesia

3) Department of Ophthalmology, Hasanuddin University, Jln. Perintis Kemerdekaan KM.11, RSP Unhas, Tamalanrea, Makassar, South Sulawesi 90245, Indonesia

4) Medical Department, Faculty of Medicine and Health Sciences, UIN Alauddin University, Makassar City, South Sulawesi, Indonesia

5) Department of Epidemiology, Infectious Disease Control, and Prevention. Institute of Biomedical and Health Sciences, Hiroshima University, 1-2-3 Kasumi, Minami-ku, Hiroshima 734-8551, Japan

### ABSTRACT

**Purpose:** The purpose of this study was to examine the outer retinal layer thicknesses in normal and glaucomatous eyes with a Topcon 3D spectral domain optical coherence tomography (SD-OCT) instrument.

**Methods:** Fifty-nine normal eyes and 139 glaucomatous eyes were included in this study. The SD-OCT images were assessed to determine the overall average, superior, and inferior thicknesses of the inner and outer retinal layers. The macula was examined in an area of 7 × 7 mm centered on the fovea and divided into 10 × 10 grids. The thicknesses of the inner and outer macular layers in each square of the ten grids horizontally aligned below the fovea were plotted in a line graph.

**Results:** The findings indicated that all the inner retinal parameters decreased with increasing glaucoma severity. The difference in outer retinal layer thickness between the normal and all the glaucoma groups was not significant. However, the outer retinal layer thickness was significantly different for different glaucoma severity subgroups ( $P < 0.05$ ). The changes in thickness in the outer retinal layer in the ten small squares horizontally aligned under the fovea revealed significant differences between the normal control group and the various glaucoma severity subgroups.

**Conclusions:** Changes in the thickness of the outer macular retinal layer can be detected using a Topcon 3D SD-OCT 2000. The findings of this study indicate that the outer retinal layer might be involved in glaucomatous eyes.

**Key words:** Outer retinal layer thickness, inner retinal layer thickness, glaucoma, SD-OCT

### INTRODUCTION

Glaucoma is a progressive optic neuropathy that can lead to blindness. It is characterized by the death of retinal ganglion cells and corresponding defects in the visual field. In addition to general eye examinations, optical coherence tomography (OCT) is used as a non-invasive method for diagnosing glaucoma in patients suspected to have the disease. OCT-determined changes in the macular inner retinal layer, circumpapillary retinal nerve fiber layer (RNFL), and optic nerve head have been used to detect early glaucoma. Because glaucoma is associated with a decrease in macular thickness due to the death of retinal ganglion cells and their axons,

many studies have focused on studying the inner retinal layer and optic nerve head on OCT images. Some studies reported assumptions that the outer retinal layer in glaucoma subjects is intact. However, some studies that used histological methods and the newly developed adaptive optics fundus camera report that the outer retinal layer is affected in glaucomatous eyes.

The Topcon 3D SD-OCT2000 includes software programs that reduce artifacts caused by eye movement and can be used to obtain the clear retinal images. It also has layer detection algorithms that allow clinicians to objectively measure the total retina thickness and the thickness of the inner retina layer (RNFL, ganglion cell and inner plexiform layer). The outer retinal layer is made up of the outer plexiform layer, outer nuclear layer,

\* Corresponding author: Diah Gemala Ibrahim, MD  
Department of Ophthalmology and Visual Science, Graduate School of Biomedical Sciences, Hiroshima University, 1-2-3 Kasumi, Minami-Ku, Hiroshima 734-8551, Japan  
Tel: +81-82-257-5247, Fax: +81-82-257-5249, E-mail: dr.diahgemalaibrahim@gmail.com

external limiting membrane, and photoreceptors; its thickness can be obtained by subtracting the thickness of the inner retinal layer from the total retinal thickness. We can examine a macula area of  $7 \times 7$  mm centered on the fovea and divide it into  $10 \times 10$  grids<sup>1,2)</sup>.

The purpose of this study was to determine whether glaucoma alters macular thickness especially the outer retinal layer thickness. To accomplish this, we obtained SD-OCT images of the macular area using a Topcon 3D SD-OCT 2000 instrument and measured the thicknesses of different layers of the retina.

## METHODS

### Subjects

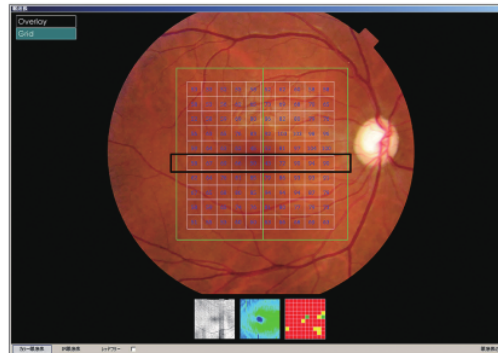
All subjects were examined in the Department of Ophthalmology Outpatient Clinic of Hiroshima University Hospital, Japan between August 2012 and January 2013. The examination procedures adhered to the tenets of the Declaration of Helsinki and were approved by the Ethics Committee of Hiroshima University. Informed consent was obtained from all subjects after providing an explanation of the purpose of the experiments and the possible complications of the examination procedures. All participants provided their written informed consent to participate in this study.

All subjects underwent standard ophthalmological examinations including the measurement of the best-corrected visual acuity, Goldmann applanation tonometry, slit-lamp biomicroscopy, gonioscopy, dilated fundus examination, color- and red-free fundus photography (Fundus camera TRC 50 EX, Topcon, Tokyo Japan) and visual field testing (SITA 24-2 standard) with an automatic static perimeter (Humphrey Field Analyzer—Carl Zeiss Meditec, Dublin, CA). In addition, SD-OCT images were obtained with the Topcon OCT (3D OCT-2000 version 7.00) (Topcon Corporation, Tokyo, Japan) following pupillary dilation. All examinations were performed on a single day for each participant.

In this study, only one eye was included for each patient. Glaucomatous eyes were defined as those with glaucomatous visual field defects and typical glaucomatous optic disc changes, i.e. notching of the optic disc or neuroretinal rim loss, focal thinning of the nerve fiber layer, disc hemorrhage or vertical elongation of the optic cup with a cup-to-disc ratio of  $> 0.7$  and inter-eye cup asymmetry of  $> 0.2$  as observed on slit-lamp biomicroscopy and fundus photography.

The visual fields are considered reliable when the fixation loss was  $< 20\%$  and false positive and negative error was  $< 15\%$ . A visual field defect was concluded to be present if the pattern deviation probability plot showed a cluster of three or more contiguous points that were significantly different ( $P < 0.05$ ) with at least one difference at the  $P < 0.01$  level on the same side of the horizontal meridian, the pattern standard deviation (PSD) had a value of  $< 5\%$  of the normal reliable field or a glaucoma hemifield test indicated that the field was abnormal.

The severity of glaucoma was determined using the



**Figure 1** Fundus photograph with the  $7 \times 7$  mm scan map superimposed. The  $10 \times 10$  grid of the Topcon 3D SD-OCT 2000 is divided into 100 squares, and the thickness of each square is shown for this glaucoma patient. The data in the horizontal line below the fovea, surrounded by the rectangle, were used for the statistical analyses. We defined that Grid 1 is located at the nearest position to the optic disc and Grid 10 is located at the temporal end of grid line.

modified Hodapp-Anderson-Parrish grading scale based on the mean deviation (MD) of the visual field. Early glaucoma was defined to be present in the eye when the MD of the visual field was  $\geq -6$  dB, moderate glaucoma was defined as eyes with an MD of  $-6$  to  $-12$  dB and severe glaucoma was defined as eyes with an MD of  $\leq -12$  dB<sup>3)</sup>. We used the data from only one eye for each patient; if both eyes met the inclusion criteria, we analyzed the data for the right eye.

The normal control subjects had no history or evidence of intraocular surgery and had intraocular pressure (IOP) values  $< 22$  mmHg. The control subjects also had no visual field defects or abnormal ophthalmological findings that indicated the presence of any disease except for mild cataracts and refractive errors. All the normal and glaucoma subjects had refractive errors between  $+3.00$  and  $-6.00$  diopters (D).

### Optical coherence tomographic (OCT) measurements

The Topcon 3D OCT-2000 system was used to scan the posterior pole of the eye. The macula was examined with  $512 A \times 128 B$  scans covering an area of  $7 \times 7$  mm centered on the fovea and divided into  $10 \times 10$  grids<sup>1,2,6)</sup>. The thickness of each layer in each grid was measured and exported to a computer using the software program provided by Topcon, Inc.<sup>1)</sup> The thickness of the combined retinal ganglion cell layer (GCL) and inner plexiform layer (IPL) was referred to as the GCL+ layer. The thickness of these two layers plus the RNFL thickness was referred to as the GCL++ layer. We also determined the differences in the thickness parameters in a horizontal grid line just inferior to the fovea (Figure 1).

The circumpapillary RNFL thickness was measured using the 3-dimension optic disc measurement ( $512 A$ -scans  $\times 128 B$ -scans) covering an area of  $6 \times 6$  mm centered on the optic disc. Images were not used when the

**Table 1** Demographic data of the study subjects.

Parameters	N (n = 59)	G (n = 139)	P*	Glaucoma			P <sup>†</sup>
				EG (n = 72)	MG (n = 24)	SG (n = 43)	
Age (years)	56.68 ± 18.01	61.28 ± 16.21	0.122	59.6 ± 16	62.5 ± 15.93	63.41 ± 16.76	0.437
Sex (F/M)	30/29	71/68	0.976	43/29	12/12	16/28	0.063
IOP (mmHg)	15.49 ± 2.9	14.91 ± 4.26	0.059	15.39 ± 4.38	15.17 ± 5.55	13.98 ± 2.98	0.242
SE (D)	-2.05 ± 2.59	-2.73 ± 2.77	0.158	-2.64 ± 2.39	-2.69 ± 3.44	-2.86 ± 2.50	0.928
MD (dB)	-0.45 ± 1.39	-8.6 ± 8.56	< 0.0001	-1.93 ± 1.81	-9.14 ± 1.91	-19.45 ± 6.04	< 0.0001
PSD (dB)	1.63 ± 0.23	6.8 ± 4.52	< 0.0001	3.37 ± 2.35	9.47 ± 3.29	11.05 ± 3.00	< 0.0001

The data are expressed as the mean ± SD.

N: normal; G: glaucoma; EG: early glaucoma; MG: moderate glaucoma; SG: severe glaucoma

F/M: female/male; IOP: intraocular pressure; SE: spherical equivalent; MD: mean deviation; PSD: pattern standard deviation

\* Significant difference between normal and glaucomatous eyes calculated with the Mann-Whitney U test

† Significant difference among the glaucoma subgroups calculated with the Kruskal-Wallis test

measurement circle was decentered. All the measurements except for the subjects' characteristics and circumpapillary RNFL thicknesses were transferred to a computer using the Topcon Data Collector (Topcon) for the statistical analyses. Images with a quality factor or signal strength of > 70 were used for the analyses<sup>1</sup>.

### Statistical analyses

The significance of the differences in the macula scan components, RNFL, GCL+, GCL++ and outer retinal layer thicknesses of the normal eyes and all the glaucomatous eyes was determined using the Mann-Whitney U test. The Kruskal-Wallis non-parametric test was used to compare the findings among the various glaucoma severity subgroups. The thicknesses of the RNFL, GCL+, GCL+++ and outer retinal layer in each square in the 10 × 10 grid aligned on a horizontal line below the fovea were plotted in a line graph. Comparisons of the data on the horizontal line between the normal and glaucoma groups and among the various glaucoma severity subgroups were made using the Mann-Whitney U test. Multiple comparisons of the inner and outer retinal layer parameters of the 10 × 10 grid on a horizontal line below the fovea between the normal group and the various glaucoma subgroups were made using the Kruskal-Wallis non-parametric test and post-hoc Steel-Dwass test. A P value of < 0.05 was considered statistically significant. Statistical analyses were performed using the JMP 9.0 version software program (SAS Institute Inc. Cary, NC).

## RESULTS

One hundred and ninety-eight eyes, including 59 normal eyes and 139 glaucomatous eyes (72 eyes with early glaucoma, 24 eyes with moderate glaucoma and 43 eyes with severe glaucoma), were studied. The characteristics of the subjects, including age, sex, IOP, refractive error (spherical equivalent), mean deviation (MD) and pattern standard deviation (PSD), are shown in Table 1. Statistical analyses showed the differences in the demographic data between the normal and glaucoma groups were not significant, except for the MD and PSD ( $P < 0.0001$ ) values. Among the glaucoma subgroups, the differences in

age, sex, IOP, and refractive errors were not significant, but the MD and PSD values were significantly different ( $P < 0.0001$  for both).

### Changes in the inner retinal layer thickness

The RNFL, GCL+ and GCL++ were thickest in the normal group and the thickness of these layers decreased as the severity of glaucoma increased in the glaucoma groups. The differences in the thickness of these layers between the various glaucoma severity subgroups were significant ( $P < 0.0001$ ; Table 2). The thicknesses of the RNFL, GCL+ and GCL++ in the normal and glaucoma groups for each of the ten squares on a horizontal line below the fovea are plotted in Figure 2.

### Changes in the outer retinal thickness

The SD-OCT findings for the different parts of the outer retinal layer in the normal and glaucoma groups are shown in Table 3. The Mann-Whitney U test showed no significant differences in the outer retinal layer thickness between the normal group and all the glaucoma subgroups. Comparisons among the different glaucoma severity subgroups made using the Kruskal-Wallis test showed that all thicknesses were significantly different: the average thickness of the outer retinal layer ( $P = 0.009$ ), the superior outer retinal layer thickness ( $P = 0.022$ ), and the inferior outer retinal layer thickness ( $P = 0.005$ ).

The changes in the thickness of the outer retinal layer in the ten small squares horizontally aligned under the fovea are shown in Figure 3 (a-d). There were no significant differences between the normal control group and all the glaucoma severity subgroups at any point ( $P = 0.1203$ ). The differences between the normal group and the various glaucoma severity subgroups were significant. The average thickness of the outer retinal layer in the ten squares for the normal group was significantly thicker than that observed in the early glaucoma group ( $P < 0.0001$ ) and thinner than that observed in the moderate glaucoma group ( $P < 0.0001$ ) and severe glaucoma group ( $P = 0.006$ ). The outer retina of the early stage glaucoma group was thinner than that observed in the normal controls at the seven central points in the ten small square lines under the fovea ( $P < 0.05$ ). For the



**Table 2** Inner retinal layer thickness as determined using Topcon 3D SD-OCT 2000 images.

Parameters (µm)	Normal (n = 59)	Glaucoma (n = 139)	P*	Glaucoma			P†
				EG (n = 72)	MG (n = 24)	SG (n = 43)	
RNFL average	36.67 ± 4.9	26.3 ± 8.6	< 0.0001	30.43 ± 6.87	25.19 ± 9.06	20.01 ± 6.91	< 0.0001
RNFL superior	34.9 ± 4.83	26.85 ± 8.8	< 0.0001	30.68 ± 7.26	26.33 ± 9.42	20.74 ± 7.31	< 0.0001
RNFL inferior	38.44 ± 5.9	25.68 ± 10.47	< 0.0001	30.1 ± 8.86	24.06 ± 11.61	19.17 ± 8.67	< 0.0001
GCL++ average	107.23 ± 8.6	85.04 ± 15.05	< 0.0001	92.3 ± 11.78	82.04 ± 16.89	74.57 ± 12.09	< 0.0001
GCL++ superior	106.28 ± 9.2	86.59 ± 16.19	< 0.0001	93.62 ± 12.9	84.13 ± 18.22	76.2 ± 14.11	< 0.0001
GCL++ inferior	108.18 ± 8.82	83.37 ± 17.09	< 0.0001	90.85 ± 14.22	79.96 ± 20.19	72.74 ± 13.28	< 0.0001
GCL+ average	70.19 ± 5.56	58.63 ± 7.7	< 0.0001	61.64 ± 6.26	56.85 ± 8.99	54.57 ± 7.06	< 0.0001
GCL+ superior	70.94 ± 5.8	59.72 ± 8.49	< 0.0001	62.91 ± 6.91	57.8 ± 9.67	55.46 ± 8.19	< 0.0001
GCL+ inferior	69.45 ± 5.56	57.47 ± 8.27	< 0.0001	60.31 ± 6.98	55.9 ± 10.32	53.58 ± 7.28	< 0.0001

The data are expressed as the mean ± SD.

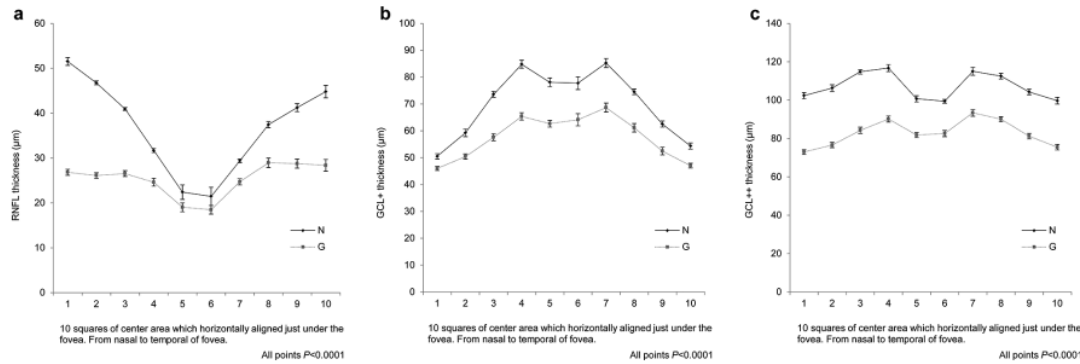
(GCL+): Combination of retinal ganglion cell layer (GCL) and inner plexiform layer (IPL) thickness;

(GCL++): Combination of GCL, IPL, and RNFL thickness.

\* Significant difference between the normal and glaucoma group calculated with the Mann-Whitney U test

† Significant difference among the glaucoma severity subgroups calculated with the Kruskal-Wallis test

EG indicates early glaucoma; MG indicates moderate glaucoma; SG indicates severe glaucoma.



**Figure 2** (a, b, c) Thickness of the retinal nerve fiber layer (RNFL), ganglion cell layer +inner plexiform layer thickness (GCL+) and the three-layer combination of RNFL, ganglion cell layer, and inner plexiform layer thickness (GCL++) assessed with the Topcon 3D SD-OCT 2000. (a) Comparison of the RNFL thickness between the normal eyes (N) and all glaucomatous eyes (G). (b) Comparison of the GCL+ thickness between the normal eyes (N) and all glaucomatous eyes (G). (c) Comparison of the GCL++ thickness of the normal eyes (N) and all glaucomatous eyes (G). The points are expressed as the mean. The error bars are expressed as the standard error.

**Table 3** Outer retinal layer thickness as determined using 3D OCT-2000 Topcon images.

Parameters (µm)	Normal (n = 59)	Glaucoma (n = 139)	P*	Glaucoma			P†
				EG (n = 72)	MG (n = 24)	SG (n = 43)	
Outer retinal layer average	154.38 ± 8.01	153.84 ± 9.31	0.671	151.42 ± 7.99	157.27 ± 10.09	155.97 ± 9.99	0.009
Outer retinal layer superior	156.64 ± 8.47	155.9 ± 9.94	0.584	153.72 ± 8.27	159.17 ± 10.77	157.74 ± 11.31	0.022
Outer retinal layer inferior	152.13 ± 8.08	151.72 ± 9.92	0.857	149.1 ± 8.46	155.2 ± 11.67	154.16 ± 10.16	0.005

The data are expressed as the mean ± SD.

\* Significant difference between the normal and glaucoma calculated with the Mann-Whitney U test

† Significant difference among the glaucoma subgroups calculated with the Kruskal-Wallis test

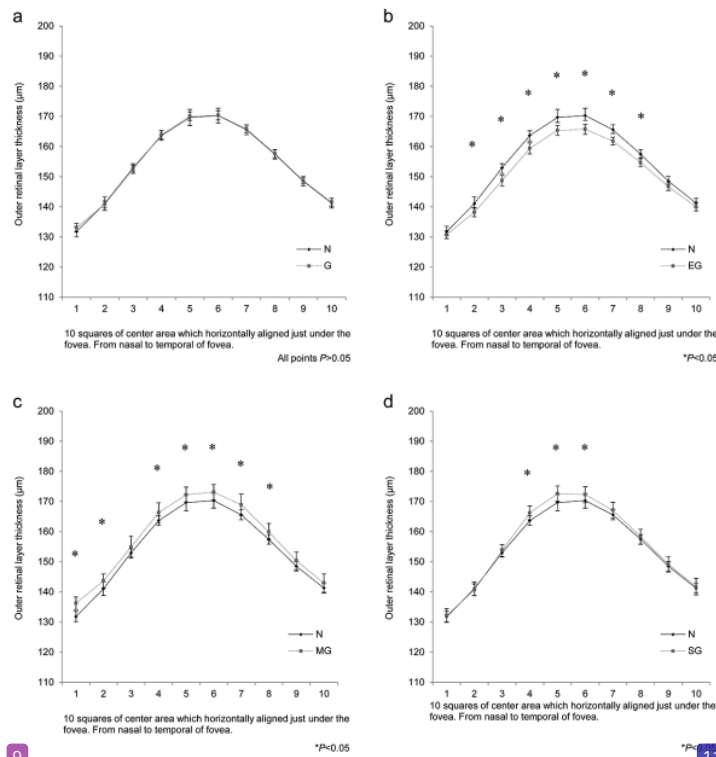
EG indicates early glaucoma; MG indicates moderate glaucoma; SG indicates severe glaucoma.

moderate and severe glaucoma groups, the outer retina was thicker than that observed in the normal subjects. Significant differences were found at seven points in the moderate glaucoma group and three points at the foveal area in the severe glaucoma group ( $P < 0.05$ ). The data showed that the most affected area in the three stages of glaucoma severity is located on grid 5 and 6, which is

where the fovea is located.

**Multiple comparisons in a 10 × 10 grid on a horizontal line**

The results of the multiple comparisons tests for outer retinal layer parameters in the normal, early glaucoma, moderate glaucoma and severe glaucoma groups were



**Figure 3** (a, b, c, d) Thickness of the outer retinal layer assessed with the Topcon 3D SD-OCT 2000. a. Comparison of the outer retinal layer thickness between the normal eyes (N) and all glaucomatous eyes (G). b. Comparison of the outer retinal layer thickness between the normal eyes (N) and early stage glaucomatous eyes (EG). c. Comparison of the outer retinal layer thickness between the normal eyes (N) and moderate stage glaucomatous eyes (MG). d. Comparison of the outer retinal layer thickness between the normal eyes (N) and severe stage glaucomatous eyes (SG). The points are expressed as the mean. The error bars are expressed as the standard error.

outlined in a  $10 \times 10$  grid on a horizontal line below the fovea, as shown in Table 4. We defined that Grid 1 is at the temporal end of the grid line and Grid 10 is located at nearest position to the optic disc. Using the Kruskal-Wallis test revealed significant differences in the central area of the fovea, as presented in Grids 3 to 8.

**DISCUSSION**

SD-OCT images showed that the inner retinal macular parameters (GCL+ and GCL++) and the thickness of the circumpapillary RNFL decreased in association with an increase in the severity of glaucoma. SD-OCT analyzes the retinal thicknesses in a  $7 \times 7$  mm area centered on the fovea, including the total, superior and inferior areas. We also decided to examine the thickness along a horizontal line just inferior to the fovea because the inferior part of the fovea is more sensitive to early changes in glaucoma. Our findings showed a decrease in the inner retinal layer thickness in this horizontal area. The OCT device was able to detect changes in the outer retina in the glaucoma patients. The changes in the outer retinal thickness were smaller than those observed in the inner retinal thickness. The differences in the capacity of the

OCT devices to detect small changes may account for the inconsistencies in study reports to some extent. The results regarding the inner retinal layers in the present study are consistent with the findings of earlier studies, thus indicating that our SD-OCT instruments and techniques provide valid results for examining outer retinal changes in subjects with glaucoma.

The Topcon 3D SD-OCT 2000 system averaged the total macular area, the superior sector and inferior sector, and did not find any significant differences in the outer retinal thickness between the normal and total glaucomatous eyes for these regions. However, our results showed that the differences in the outer retinal layer thickness between the glaucoma severity subgroups were significant. We expected that our small grid analysis may demonstrate this phenomenon, following the results of Fan et al. Our results showed that the outer retinal layer in the early glaucoma group was significantly thinner; the moderate and severe glaucoma groups had outer retinal layers significantly thicker than those observed in the normal group. Significant differences between the normal and severe glaucoma groups, and between the normal and moderate glaucoma groups were observed in the central fovea area, which correlates

**Table 4** Multiple comparisons for the outer retinal layer thickness parameter in the horizontal line below the fovea.

Grid	Group				P*	P†
	N	EG	MG	SG		
Grid 1	146.85 ± 13.61	142.68 ± 10.81	152.09 ± 27.97	144.90 ± 15.24	0.0517	N-EG: 0.0440
Grid 2	158.42 ± 17.04	155.30 ± 12.82	162.58 ± 11.32	160.31 ± 12.77	0.0298	NA
Grid 3	172.52 ± 10.75	167.71 ± 15.22	177.09 ± 17.65	177.72 ± 12.99	0.0001	EG-MG: 0.0215 EG-SG: 0.0004
Grid 4	181.06 ± 11.75	175.91 ± 15.56	184.18 ± 18.93	186.76 ± 14.92	< 0.0001	N-EG: 0.0429 N-SG: 0.0302 EG-MG: 0.0157 EG-SG: < 0.0001
Grid 5	178.76 ± 20.46	172.48 ± 13.82	178.42 ± 21.36	181.24 ± 16.75	0.0023	EG-SG: 0.0012
Grid 6	184.51 ± 18.62	177.51 ± 13.96	184.58 ± 21.68	186.45 ± 21.06	0.0038	EG-MG: 0.0386 EG-SG: 0.0121
Grid 7	187.41 ± 12.51	182.37 ± 10.75	192.51 ± 17.46	191.83 ± 17.69	< 0.0001	EG-MG: 0.0315 EG-SG: 0.0001
Grid 8	177.88 ± 12.11	173.77 ± 10.93	178.39 ± 13.55	180.73 ± 21.69	0.0021	EG-SG: 0.0010
Grid 9	163.17 ± 12.10	160.38 ± 10.52	163.25 ± 14.26	165.18 ± 16.89	0.0593	EG-SG: 0.0318
Grid 10	146.05 ± 12.81	145.89 ± 12.16	148.57 ± 15.09	150.92 ± 20.95	0.0616	EG-SG: 0.0451

The data are expressed as the mean ± SD.

\* Significant difference calculated with the Kruskal-Wallis non-parametric test

† Significant difference calculated with the post-hoc Steel-Dwass multiple comparisons test

N indicates normal; EG indicates early glaucoma; MG indicates moderate glaucoma;

SG indicates severe glaucoma.

Grid 1 is located at the nearest position to the optic disc and Grid 10 is located at the temporal end of the grid line.

with the findings of Fan et al.<sup>6)</sup>

There are several reports that the outer retinal layer is not altered in glaucomatous eyes. A study conducted by Vajaranant et al.<sup>25)</sup> found that the outer retinal thickness determined with Stratus time domain OCT in glaucoma subjects was not altered in comparison to that observed in the control subjects. In another study, Tan et al.<sup>24)</sup> evaluated the macular area of glaucoma patients with Stratus time domain OCT and concluded that alterations in the outer retinal layer thickness were minimal compared to the alterations in the inner retinal layer thickness. Similar findings were reported by Schulze et al.<sup>21)</sup> using RT-Vue SD-OCT. The idea that glaucoma affects the inner retinal layer and leaves the outer retinal layer intact is accepted by many ophthalmologists<sup>15,22)</sup>. However, few researchers have documented the changes that occur in the outer retinal layer. Ishikawa et al.<sup>11)</sup>, using Stratus time domain OCT, found that the outer retinal layer (outer nuclear layer and photoreceptor layer) is thicker in glaucomatous eyes (mean MD =  $-6.87 \pm 5.15$  dB) than in normal eyes. However, their findings remain controversial. The thickness of the outer retinal layer on Topcon 3D SD-OCT 1000 images was determined by Fan et al.<sup>6)</sup> The authors examined 47 glaucoma patients; however, they did not divide the eyes into groups based on the severity of glaucoma. In their study, the average visual field MD in the glaucoma group was  $-9.91 \pm 8.29$  dB; the authors focused on the thicknesses of the parafovea and foveola, which are known to have the highest density of cones. They manually segmented the outer retina from the total retina and reported that the foveal outer retinal layer in normal eyes was significantly thicker than that observed in glaucomatous eyes. We also

paid attention to the small area near the fovea and found thickness changes in the outer retina in glaucoma subjects. More recently, by using SD-OCT, Ha et al noted that the ellipsoid portion of photoreceptor inner segment intensity was altered in accordance with severity of glaucoma. The ellipsoid zone (EZ) intensity reduction was observed from mild to severe glaucoma but not in preperimetric glaucoma. This finding suggests that during glaucoma progression, mitochondria in the inner segment of photoreceptors might be affected<sup>10)</sup>. We assumed the photoreceptor alteration that showed through EZ changes might manifest in outer retinal layer thickness.

There are only a few histological studies that have investigated the involvement of the photoreceptors in the pathogenesis of glaucoma. Kendell et al.<sup>13)</sup> did not find any significant differences in the outer nuclear layer thickness or density of the nuclei in the outer nuclear layer between nine normal eyes and 14 glaucoma eyes. Panda and Jonas<sup>19)</sup> examined 23 painful eyes that were enucleated after secondary angle-closure glaucoma and found a decrease in the number of photoreceptors. They concluded that glaucoma may be associated with photoreceptor cell loss. Nork et al.<sup>18)</sup> examined 128 glaucomatous eyes and 90 normal eyes obtained post-mortem. Their results showed that the cone nuclei at the outer border of the outer nuclear layer were enlarged and the somata were swollen in a subset of the glaucomatous eyes. Cone and somata swelling would underlie the apparent outer nuclear layer thickness and outer retinal layer. Although the results from histological studies are not completely consistent, three studies<sup>10,18,26)</sup> reported cell density or size changes in the outer retina. The severity of glaucoma, different measurement areas, and the



methods used to diagnose glaucoma tended to differ among studies. This may be the reason for the discrepancies observed in the histological results.

Recently, Choi et al.<sup>4)</sup> and Werner et al.<sup>27)</sup> evaluated normal subjects and patients with glaucoma using an adaptive optics fundus camera to determine the cone density and the length of the photoreceptors. They found a reduction in the length of the cone photoreceptor outer segments in glaucomatous eyes along with a reduction in the cone density in the same areas and concluded that glaucomatous optic neuropathy is associated with outer retinal changes following inner retinal pathology. However, they did not mention what caused the changes seen in the outer retina. Nork et al.<sup>18)</sup> introduced two possibilities regarding both photoreceptor pathology and ganglion cell death in glaucoma. First, changes in photoreceptors could be caused by an effect of the disease that is independent of ganglion cell injury. Secondly, reduced choroidal blood flow causes ischemia and swelling of the photoreceptors thus resulting in a decrease in the reuptake of glutamate. The retinal ganglion cells undergo apoptosis because of glutamate overload. Changes in the layer thickness of photoreceptors in moderate and severe glaucoma patients could be caused by the pre-apoptosis process of the photoreceptor prior to death. Ha et al.<sup>10)</sup> added another possible explanation by pointing out the negative effect of glial cells in photoreceptors after prolonged stress associated with glaucomatous change. Glial cells that provide photoreceptor neuroprotection in normal conditions shift to being neurodestructive by releasing amounts of neurotoxic substances. These alterations may trigger the functional photoreceptor cell changes in severe glaucoma but not in early glaucoma since glial cells still support the photoreceptors at that point. These phenomena are all just speculation. As a result, the mechanism by which glaucoma damages the outer retinal layers still remains to be elucidated.

Our study had several limitations. First, the cross-sectional study design limits its strength in determining a clear directional association. Secondly, the number of subjects was small. Future studies with larger patient populations is therefore needed, especially to determine the correlation between the outer retinal layer thickness and the severity of glaucoma, because the changes in outer retinal layer thickness are not sizeable. Thirdly, even though we applied inclusion and exclusion criteria, there may potentially have been other variables present that were not accounted for and that may have affected the retinal layer thickness, for example, the different numbers of anti-glaucoma medication used in each severity category of glaucoma. Anti-glaucoma drugs, including latanoprost, have been shown to have a neuroprotective effect on the inner retinal layer<sup>12,16)</sup>. The combination of latanoprost and timolol has also been demonstrated to have an increased neuroprotective effect better than that of monotherapy<sup>7)</sup>. Thus, increased combination of anti-glaucoma drugs is believed to have an effect on inner retinal layer thickness. However, we could not generalize that anti-glaucoma drugs affect

outer retinal layer as well. In general, there is insufficient quantitative data on the effect of anti-glaucoma drugs on photoreceptors or the outer retinal layer to explain the possible effect of anti-glaucoma medication on the outer retinal layer. Further study is necessary to demonstrate the possible effect of anti-glaucoma drugs on the retinal layers in each severity stage of glaucoma.

In conclusion, the SD-OCT instrument detected changes in the outer retinal layer in glaucoma subjects. Based on these findings, we conclude that changes in the outer retinal layer thickness may be related to the glaucoma disease process; however, we cannot explain why the outer retinal layer thickness is thinner in the early stage of glaucoma than in normal eyes and thicker in the moderate and severe stages of glaucoma. Future improvements in OCT instruments will allow clinicians to confirm the hypothesis that there is involvement of the outer retinal layer in eyes with glaucoma.

## ACKNOWLEDGEMENT

We thank Dr. Brian Quinn for English language editing.

## Conflict of Interest

All authors declare that there is no conflict of interest.

(Received January 10, 2019)

(Accepted April 1, 2019)

## REFERENCES

1. Akashi, A., Kanamori, A., Nakamura, M., Fujihara, M., Yamada, Y. and Negi, A. 2013. Comparative assessment for the ability of Cirrus, RTVue, and 3D-OCT to diagnose glaucoma. *Investigative ophthalmology & visual science* 54: 4478–4484.
2. Akashi, A., Kanamori, A., Nakamura, M., Fujihara, M., Yamada, Y. and Negi, A. 2013. The ability of macular parameters and circumpapillary retinal nerve fiber layer by three SD-OCT instruments to diagnose highly myopic glaucoma. *Investigative ophthalmology & visual science* 54: 6025–6032.
3. Arintawati, P., Sone, T., Akita, T., Tanaka, J. and Kiuchi, Y. 2013. The applicability of ganglion cell complex parameters determined from SD-OCT images to detect glaucomatous eyes. *Journal of Glaucoma* 22: 713–718.
4. Choi, S.S., Zawadzki, R.J., Lim, M.C., Brandt, J.D., Keltner, J.L., Doble, N., et al. 2011. Evidence of outer retinal changes in glaucoma patients as revealed by ultrahigh-resolution in vivo retinal imaging. *The British journal of ophthalmology* 95: 131–141.
5. Chrastek, R., Wolf, M., Donath, K., Niemann, H., Paulus, D., Hothorn, T., et al. 2005. Automated segmentation of the optic nerve head for diagnosis of glaucoma. *Medical image analysis* 9: 297–314.
6. Fan, N., Huang, N., Lam, D.S.C. and Leung, C.K-s. 2011. Measurement of Photoreceptor Layer in Glaucoma: A Spectral-Domain Optical Coherence Tomography Study. *Journal of ophthalmology* 264803.
7. Fuma, S., Shimazawa, M., Imamura, T., Kanno, Y., Takano, N., Tsuruma, K., et al. 2016. Neuroprotective Effect of Ocular Hypotensive Drugs: Latanoprost/



- Timolol in Combination Are More Effective than Each as Monotherapy in RGC-5. *Biological & pharmaceutical bulletin* 39: 192–198.
8. Gonzalez-Garcia, A.O., Vizzeri, G., Bowd, C., Medeiros, F.A., Zangwill, L.M. and Weinreb, R.N. 2009. Reproducibility of RTVue retinal nerve fiber layer thickness and optic disc measurements and agreement with Stratus optical coherence tomography measurements. *American journal of ophthalmology* 147: 1067–1074, 1074.e1061.
  9. Guo, L., Normando, E.M., Nizari, S., Lara, D. and Cordeiro, M.F. 2010. Tracking longitudinal retinal changes in experimental ocular hypertension using the cSLO and spectral domain-OCT. *Investigative ophthalmology & visual science* 51: 6504–6513.
  10. Ha, A., Kim, Y.K., Jeoung, J.W. and Park, K.H. 2018. Ellipsoid Zone Change According to Glaucoma Stage Advancement. *American journal of ophthalmology* 192: 1–9.
  11. Ishikawa, H., Stein, D.M., Wollstein, G., Beaton, S., Fujimoto, J.G. and Schuman, J.S. 2005. Macular segmentation with optical coherence tomography. *Investigative ophthalmology & visual science* 46: 2012–2017.
  12. Kanamori, A., Naka, M., Fukuda, M., Nakamura, M. and Negi, A. 2009. Latanoprost protects rat retinal ganglion cells from apoptosis in vitro and in vivo. *Experimental eye research* 88: 535–541.
  13. Kendell, K.R., Quigley, H.A., Kerrigan, L.A., Pease, M.E., and Quigley E.N. 1995. Primary open-angle glaucoma is not associated with photoreceptor loss. *Investigative ophthalmology & visual science* 36: 200–205.
  14. Kita, Y., Kita, R., Takeyama, A., Takagi, S., Nishimura, C. and Tomita, G. 2013. Ability of optical coherence tomography-determined ganglion cell complex thickness to total retinal thickness ratio to diagnose glaucoma. *Journal of Glaucoma* 22: 757–762.
  15. Kita, Y., Naghizadeh, F., Kita, R., Tomita, G. and Hollo, G. 2013. Comparison of macular ganglion cell complex thickness to total retinal thickness ratio between Hungarian and Japanese eyes. *Japanese journal of ophthalmology* 57: 540–545.
  16. Kudo, H., Nakazawa, T., Shimura, M., Takahashi, H., Fuse, N., Kashiwagi, K., et al. 2006. Neuroprotective effect of latanoprost on rat retinal ganglion cells. *Graefe's archive for clinical and experimental ophthalmology = Albrecht von Graefes Archiv fur klinische und experimentelle Ophthalmologie* 244: 1003–1009.
  17. Nakatani, Y., Higashide, T., Ohkubo, S., Takeda, H. and Sugiyama, K. 2011. Evaluation of macular thickness and peripapillary retinal nerve fiber layer thickness for detection of early glaucoma using spectral domain optical coherence tomography. *Journal of Glaucoma* 20: 252–259.
  18. Nork, T.M., Ver Hoeve, J.N., Poulsen, G.L., et al. 2000. Swelling and loss of photoreceptors in chronic human and experimental glaucomas. *Archives of ophthalmology* (Chicago, Ill: 1960). 118: 235–245.
  19. Panda, S. and Jonas, J.B. 1992. Decreased photoreceptor count in human eyes with secondary angle-closure glaucoma. *Investigative ophthalmology & visual science* 33: 2532–2536.
  20. Rimayanti, U., Latief, M.A., Arintawati, P., Akita, T., Tanaka, J. and Kiuchi, Y. Width of abnormal ganglion cell complex area determined using optical coherence tomography to predict glaucoma. *Japanese journal of ophthalmology* 58: 47–55.
  21. Schulze, A., Lamparter, J., Pfeiffer, N., Berisha, F., Schmidtman, I. and Hoffmann, E.M. 2011. Diagnostic ability of retinal ganglion cell complex, retinal nerve fiber layer, and optic nerve head measurements by Fourier-domain optical coherence tomography. *Graefe's archive for clinical and experimental ophthalmology* 249: 1039–1045.
  22. Takeyama, A., Kita, Y., Kita, R. and Tomita, G. 2014. Influence of axial length on ganglion cell complex (GCC) thickness and on GCC thickness to retinal thickness ratios in young adults. *Japanese journal of ophthalmology* 58: 86–93.
  23. Tan, O., Chopra, V., Lu, A.T.-H., Schuman, J.S., Ishimawa, H., Wollstein, G., et al. 2009. Detection of macular ganglion cell loss in glaucoma by Fourier-domain optical coherence tomography. *Ophthalmology* 116: 2305–2314.e2.
  24. Tan, O., Li, G., Lu, A.T., Varma, R. and Huang, D. 2008. Mapping of macular substructures with optical coherence tomography for glaucoma diagnosis. *Ophthalmology* 115: 949–956.
  25. Vajaranant, T.S., Anderson, R.J., Zelkha, R., Zhang, C., Wilensky J.T., Edward, D.P., et al. 2011. The relationship between macular cell layer thickness and visual function in different stages of glaucoma. *Eye* 25: 612–618.
  26. Velten, I.M., Korth, M. and Horn, F.K. 2001. The a-wave of the dark adapted electroretinogram in glaucomas: are photoreceptors affected? *British Journal of Ophthalmology* 85: 397.
  27. Werner, J.S., Keltner, J.L., Zawadzki, R.J. and Choi, S.S. 2011. Outer retinal abnormalities associated with inner retinal pathology in nonglaucomatous and glaucomatous optic neuropathies. *Eye* 25: 279–289.

# Evaluation of Outer Retinal Layer Thickness in Normal and Glaucomatous Eyes using Spectral Domain Optical Coherence Tomography

---

## ORIGINALITY REPORT

---

15%

SIMILARITY INDEX

10%

INTERNET SOURCES

14%

PUBLICATIONS

1%

STUDENT PAPERS

---

## PRIMARY SOURCES

---

- 1** Ulfah Rimayanti, Miftahul Akhyar Latief, Paramastri Arintawati, Tomoyuki Akita, Junko Tanaka, Yoshiaki Kiuchi. "Width of abnormal ganglion cell complex area determined using optical coherence tomography to predict glaucoma", Japanese Journal of Ophthalmology, 2013  
Publication 6%

---
- 2** Ulfah Rimayanti, Yoshiaki Kiuchi, Ken Yamane, Miftahul Akhyar Latief et al. "Inner retinal layer comparisons of eyes with exudative age-related macular degeneration and eyes with age-related macular degeneration and glaucoma", Graefe's Archive for Clinical and Experimental Ophthalmology, 2013  
Publication 2%

---
- 3** [mhlw-grants.niph.go.jp](http://mhlw-grants.niph.go.jp)  
Internet Source 2%

---
- 4** [www.ncbi.nlm.nih.gov](http://www.ncbi.nlm.nih.gov)  
Internet Source

1 %

5

[www.biorxiv.org](http://www.biorxiv.org)

Internet Source

1 %

6

[acikerisim.mu.edu.tr](http://acikerisim.mu.edu.tr)

Internet Source

1 %

7

Yu Jeong Kim, Min Ho Kang, Hee Yoon Cho, Han Woong Lim, Mincheol Seong.

"Comparative study of macular ganglion cell complex thickness measured by spectral-domain optical coherence tomography in healthy eyes, eyes with preperimetric glaucoma, and eyes with early glaucoma", Japanese Journal of Ophthalmology, 2014

Publication

1 %

8

Mailankody, Pooja, Rajani Battu, Anjani Khanna, Abhishek Lenka, Ravi Yadav, and Pramod Kumar Pal. "Optical coherence tomography as a tool to evaluate retinal changes in Parkinson's disease", Parkinsonism & Related Disorders, 2015.

Publication

1 %

9

[www.nature.com](http://www.nature.com)

Internet Source

1 %

10

[1library.net](http://1library.net)

Internet Source

1 %



11 Hiroko Inuzuka. "Macular Retinal Thickness in Glaucoma With Superior or Inferior Visual Hemifield Defects :", Journal of Glaucoma, 08/2011 1 %  
Publication

---

12 [www.dovepress.com](http://www.dovepress.com) 1 %  
Internet Source

---

Exclude quotes On

Exclude matches < 1%

Exclude bibliography On